

A Survey of Gastrointestinal Parasites of Olive Baboons (*Papio anubis*) in Human Settlement Areas of Mole National Park, Ghana

Sadie J. Ryan*, Justin S. Brashares†, Chesley Walsh‡, Katherine Milbers‡, Cailean Kilroy§, and Colin A. Chapman‡, *Department of Environmental and Forest Biology, SUNY College of Environmental Science and Forestry, 1 Forestry Drive, Syracuse, New York 13210; †Department of Environmental Science, Policy & Management, University of California, Berkeley, California 94760; ‡Department of Anthropology & McGill School of Environment, McGill University, 855 Sherbrooke Street West, Montreal, Quebec, Canada, H3A 2T7; §National Center for Ecological Analysis and Synthesis (NCEAS), University of California at Santa Barbara, Santa Barbara, California 93101. e-mail: sjryan@esf.edu

ABSTRACT: Fecal samples from 55 free-ranging olive baboons (*Papio anubis*) in Mole National Park, Ghana, were collected 22 June–7 July 2008 and analyzed for gastrointestinal parasites. This is the first survey of baboon gastrointestinal parasites in Ghana and provides baseline data for this area. Ninety-three percent of samples were infected, leaving 7% with no parasites observed. Of those infected, there was a 76% prevalence of strongyles, 53% *Strongyloides* spp., 11% *Abbreviata caucasica*, 62% prevalence of *Balantidium coli* (trophozoites and cysts identified), 4% *Entamoeba histolyticaldispar*, and 47% unidentified protozoan parasites. Of the strongyle infections, 9% were identified as *Oesophagostomum* sp. One sample contained an unidentified spirurid nematode that resembled *Gongylonema* sp. Mole has a mixed forest-savanna habitat, and baboons frequently range into human areas, which makes them subject to parasites from each habitat and multiple sources of exposure. We found a high prevalence of nematode parasites, consistent with a wet or cooler forest environment, or high rates of fecal contamination. The presence of *Strongyloides* sp., *E. histolyticaldispar*, and *B. coli* suggest potential public health risk from baboons, but molecular identification of these parasites, and documentation of their presence in local human populations, would be necessary to confirm zoonotic transmission.

The widespread expansion of mesopredators, i.e., predators of intermediate body size, has resulted in dramatic changes to a variety of ecosystems (Crooks and Soule, 1999; Prugh et al., 2009). However, surprisingly little work has considered how the changes in trophic structure and species interactions created by mesopredator eruptions may alter the ecology and dynamics of wildlife disease (Dobson et al., 2006; Keesing et al., 2011). The first step in such an assessment is surveying the diseases common to rapidly expanding mesopredator populations, such as baboons (*Papio* spp.). In Mole National Park (Mole), Ghana, and many other parks in Ghana and other African countries, populations of large predators have sharply declined, but baboons, able to exploit human-altered landscapes, are increasing in number, increasing in crop-raiding intensity, and even becoming top predators in their ecosystem (Brashares, 2003; Brashares et al., 2010; Estes et al., 2011). Here we undertook a survey of the gastrointestinal parasites (GIPs) of olive baboons (*Papio anubis*) in Mole National Park (Mole), Ghana.

An increase in both the abundance and distribution of olive baboons has been linked to intensified human-baboon interaction and conflict across much of sub-Saharan Africa (Naughton-Treves et al., 1998; Webber et al., 2007) and higher levels of intestinal parasites in baboons and humans living near them (Brashares et al., 2010; Estes et al., 2011). Baboons are omnivorous and may feed on smaller animals, including smaller livestock, possibly exposing themselves to novel pathogens (Strum, 1975). Thus, it is important to assess the potential role of baboons as disease vectors in the spillover and spillback context, particularly along the edges of protected areas where human-wildlife contact is highest, and the dynamics of wildlife populations may impact public health (Daszak et al., 2000; Dobson and Foutopoulos, 2001; Chapman et al., 2005; Wolfe et al., 2005; Jones et al., 2008; Keesing et al., 2011).

The GIPs of savanna and desert baboons are well documented from necropsy and fecal surveys, while those of forest baboons are still largely unknown (Bezjian et al., 2008). Yet forest baboons often interact with high-density human populations. The type and prevalence of GIPs in

baboons are thought to depend on a combination of climate and habitat; i.e., high aridity is unfavorable to parasites with free-living, exposed stages, while human contact, potential interspecific exposure, and concurrent infections augment parasite levels (Bezjian et al., 2008).

Mole is an open woodland savanna, with patches of riparian forests and substantial tree cover in middle and upslope savanna (Bowell and Anshah, 1994). While largely unstudied, the fauna of Mole represents a combination of forest and savanna characteristics (Eggert et al., 2002), which may, in turn, influence the suite of parasites they harbor. The baboons range throughout the park and into human-use areas both inside (staff village, school) and on the park's edge. We observed them in trash piles (Fig. 1a), kitchens, local water supplies, and feeding with warthogs, elephants, and domesticated turkeys (Fig. 1b). Thus, they experience a range of habitats, and potential mixed-species parasite exposure, both domestic and wild.

We surveyed parasites in baboon fecal samples to provide insight into the diversity of parasites in a population of free-ranging baboons in Mole and draw attention to the potential spillover and spillback disease vector they represent. It is important to note that without genetic analyses, we cannot assess zoonotic or reverse transmission, as humans and non-human primates may be infected with closely related parasites that are morphologically similar and not shared (de Gruijter et al., 2005).

Mole National Park is the largest park (4,840 km²) in Ghana, situated in the Northern (Damongo) Region (9°11'–10°6'N, 01°22'–02°16'W, 150 m a.s.l.; Fig. 2). It is classified as Guinea savanna or open woodland savanna, with patches of savanna, rich forested riparian areas, and substantial tree cover. During a single wet season (May–October), Mole receives 950–1,100 mm of annual rainfall (Lawson et al., 1968; Jachmann, 2008; Burton et al., 2010). Baboon troops were followed in the south of Mole, on the park's edge, around the village, school, and forested areas from 22 June to 7 July 2008, between 500 and 1800 hr, from troop resting location to troop resting location. This ensured that we could identify separate individuals in separate troops on sequential days. We collected fecal samples from individuals identified to sex (n = 55). All samples were collected immediately after defecation to avoid contamination. Samples were stored individually in 5.0-ml sterile vials in a 10% formalin solution.

Preserved samples were examined for helminth eggs, larvae, and large protozoan cysts using fecal sedimentation. To identify small protozoans, staining was used, with the stained slide examined at 100× under oil immersion. Half or one-quarter of a gram (depending on size of the original sample) of fecal material was processed per Greiner and MacIntosh (2009), and all the processed material was examined, with up to 10 slides per sample. Parasites were morphologically identified and photographed. Measurements were made to the nearest 0.1 μm ± SD using an ocular micrometer fitted to a compound microscope; parasites were photographed for further identification and documentation (see Chapman et al., 2006, for further methodological detail). The presence of larvae was recorded, but we could not determine whether worms were free-living; accordingly, larvae were excluded from the analysis. Detailed, species-level taxonomic accounts of gastrointestinal parasites of most wild primates are unavailable, so we largely identified parasites to the genus level. *Entamoeba histolytica* and *Entamoeba dispar* have cysts that are morphologically indistinguishable, so we refer to these as the *E. histolyticaldispar* complex.

Of the 55 samples, 51 (93%) were positive for GIPs; 42 (76%) were infected with strongyles, 29 (53%) with *Strongyloides* spp., 6 (11%) with *Abbreviata caucasica* (= *Physaloptera caucasica*), 2 (4%) with *E. histolyticaldispar*, and 26 (47%) with unidentified protozoan parasites. Strongyle,



FIGURE 1. (a) Baboons in a trash pile, Mole National Park, Ghana. (b) Baboons and warthogs eating kitchen scraps in the staff village, Mole National Park, Ghana.

Strongyloides sp., and *A. caucasica* samples were quantified for parasite burden (eggs/g) and show classic over-dispersion in their frequency distributions (Fig. 3). Thirty-four of the samples (62%) contained *Balantidium coli* (identified from trophozoites and cysts), which is pathogenic to humans. Five of the samples (9%) contained *Oesophagostomum* sp., and 1 contained an a nematode resembling *Gongylonema* sp.

To test for gender effects on parasite prevalence (Fig. 4), we used 2-tailed χ^2 tests. In each test, we had 22 females and 31 males (2 of the 55 individuals were of unknown sex). There was no significant effect of gender on parasite prevalence for strongyles ($\chi^2 = 0.82$, $df = 1$, $P = 0.37$), *Strongyloides* sp. ($\chi^2 = 3.07$, $df = 1$, $P = 0.08$), *B. coli* ($\chi^2 = 0.16$, $df = 1$, $P = 0.69$), or the unidentified protozoa ($\chi^2 = 0.003$, $df = 1$, $P = 0.96$); there were too few *A. caucasica*-positive samples for analysis.

We found that 93.0% of the olive baboon fecal samples ($n = 55$) were positive for parasites. There was a moderately high prevalence of nematodes and protozoans, suggesting relatively high rates of parasite

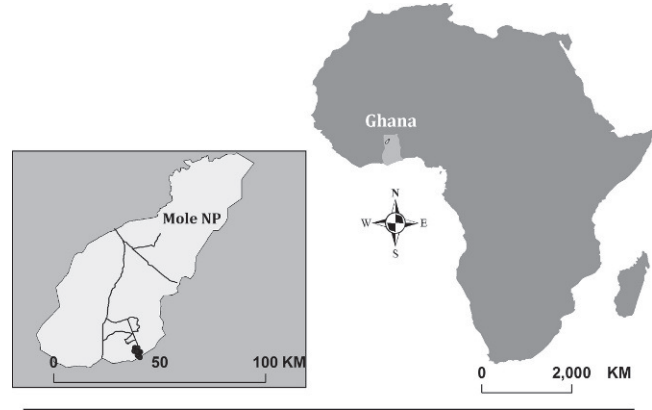


FIGURE 2. The location of Mole National Park in the north of Ghana, with an inset of Mole National Park, showing sampling locations in the south and on the park boundary (black circles).

recruitment. The high prevalence of nematode parasites is consistent with a wet, or cooler, forest environment, rather than a drier savanna (Bezjian et al., 2008), or with high rates of fecal contamination, which is possible in high-use human areas. The prevalence of *Strongyloides* (53.0%) in this study was higher than the mean prevalence in *P. anubis* populations in a synthetic review of studies of GIPs in *Papio* spp. ($43.1 \pm 5.72\%$; $\bar{x} \pm SE$) (Bezjian et al., 2008, Table II), and the prevalence of *A. caucasica* in our sample (11.0%) was lower than observed in *P. anubis* elsewhere (*Abbreviata* = *Physaloptera* sp., observed in *P. anubis*; $44.0 \pm 8.7\%$; $\bar{x} \pm SE$), (Bezjian et al., 2008). The high protozoan prevalence, particularly *B. coli*, suggests potential frequent contact with a domestic environment, although with a low sample size, we are cautious about interpretation of comparative prevalence (Jovani and Tella, 2006). Genetic analysis of the protozoan population in baboons, humans, and domestic animals would be necessary to determine if zoonotic transmission is occurring.

While *B. coli* is known to infect olive baboons and other human and non-human primates (Ash and Orihel, 1997), Weyher et al. (2006) found much higher levels in crop-raiding baboons than in wild-ranging baboons in Nigeria. They attributed this to higher anthropogenic exposure and elevated nutritional status of crop-raiding baboons. Sixty-two percent of our individuals had *B. coli* infections, suggesting that these baboons, known to range into human areas, may be experiencing moderately high levels of exposure and taking advantage of available nutrition. In addition, *B. coli* is known to infect pigs (Schuster and Ramirez-Avila, 2008) and has been recorded in the north of Ghana (Permin et al., 1999), but, for religious reasons, pigs are not a common domestic livestock animal at our site. However, warthogs are in high abundance and frequent contact in this area.

Over half of the baboons were infected with *Strongyloides* spp., a rhabditoid nematode that is relatively common in wild and domestic animals and has been found in many previous baboon parasite surveys (McGrew et al., 1989; Munene et al., 1998; Bronsdon et al., 1999; Hahn et al., 2003; Legesse and Erko, 2004; Weyher et al., 2006; Bezjian et al., 2008). One concern with *Strongyloides* spp. is the possibility of infecting humans. While there are approximately 50 recognized species, and most are thought to be quite host-specific, an artifact of the study location, i.e., isolated hosts, not interacting with alternate potential hosts (Speare, 1989). Two species, *Strongyloides fulleborni* and *Strongyloides stercoralis*, are known to infect humans; the former species occurs in African primates and is shared with humans (Hira and Patel, 1980). Since we did not identify the parasite to the species level, we cannot determine if we found a high prevalence of *S. fulleborni*, or a mixed infection of *Strongyloides*, possibly acquired from multiple sources. Clearly, further research, including genetic analysis of individual eggs, larvae, or adults, is needed to determine whether this parasite is a potential public health risk in this area, and whether this is a single, or multi-, species infection.

We found 1 sample infected with what appears to be *Gongylonema* sp. ("Gullet Worm"), a spirurid nematode that is associated with infection of the esophagus or rumen of wild, or domestic, ruminants, and has an indirect life cycle with a beetle as an intermediate host. The species *Gongylonema macrogubernaculum* has been found in non-human primates

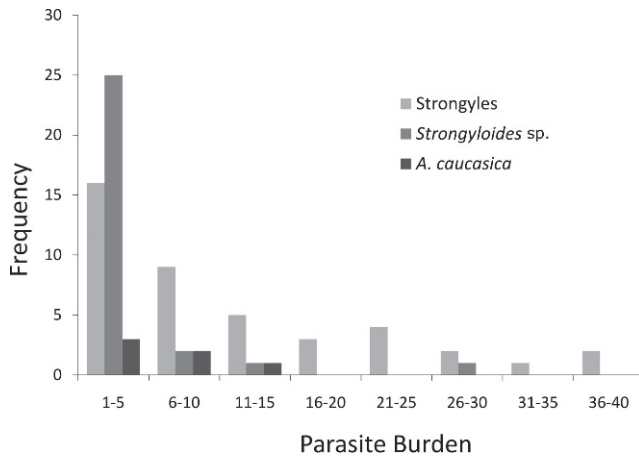


FIGURE 3. Parasite burdens (eggs per g) of strongyles, *Strongyloides* sp. and *Abbreviata caucasica*, showing classic overdispersion curves.

of African origin in captivity (Lubimov, 1931; Craig et al., 1998), but we have found no previous reports of it in free-ranging baboons. It is possible that this is a cross-specific infection, picked up from a ruminant through fecal contamination of food, either in the wild or in a domestic setting.

Entamoeba histolytica is the causative agent of amoebic dysentery and colitis in humans. It is the second most common parasite infection in humans for morbidity worldwide (Laughlin and Temesvari, 2005), and causes 40,000–100,000 human deaths annually (Ackers and Mirelman, 2006). Of an estimated 500 million new amoeba infections annually, approximately 90% are thought to be due to *E. dispar*, a morphologically identical, but non-pathogenic, species (Ackers and Mirelman, 2006). *Entamoeba histolytica* has been found to infect many captive primates, but pathogenicity in wild primates is essentially unknown (Gillespie et al., 2010). This calls for research into identification techniques for pathogenic versus non-pathogenic species, and attention to the symptoms and signs of amoebic dysentery in humans and baboons in shared areas. Given that baboons in the Mole region are frequently found sharing water sources and agricultural areas with humans, the transmission of pathogenic parasites between host species is not just plausible, but likely. While we identified *E. histolyticaldispar* in only 4% of the samples, it will be important to monitor this potential reservoir of dysentery.

In conclusion, we conducted the first survey of gastrointestinal parasites of olive baboons in Ghana. We found that baboons had moderately high levels of nematode and protozoan parasites, common to other sites, suggestive of a mixed forest and savanna habitat. We identified *Strongyloides* sp., *E. histolyticaldispar*, and *B. coli*, which may represent public health concerns for the human areas used by these baboons, although further research using genetic identification is needed to properly evaluate this concern. We also found a possible *Gongylonema* sp., suggesting potential cross-species contamination either with domestic or wild ruminants, the normal hosts. This points to potential wildlife health concerns as well, as baboon populations continue to increase in number and range.

This initial gastrointestinal parasite survey highlights a need for further investigation into (1) more in-depth parasite species identification, including genetic analyses to assess the risk to local human populations of baboon fecal contamination; (2) behavioral research into the ranging behavior of baboons in, and out of, the park, to understand the spatial extent of spillover and spillback potential; and (3) examination of the intestinal parasites in alternate wildlife host species in the area.

We thank the Wildlife Division of the Forestry Commission of Ghana for permission to work in Mole National Park; Eric Bani for help with sampling and fieldwork; Cletus Balangtaa, Warden Farouk, and David Kpelle for logistical assistance. This work was supported in part by an NSF Bioinformatics Fellowship No. 0630709 to S.J.R. and conducted while S.J.R. was a Postdoctoral Associate at the National Center for Ecological Analysis and Synthesis, a Center funded by NSF (Grant No. EF- 0553768), the University of California, Santa Barbara, and the State of California. Lab studies were supported funds provided by NSERC and C.R.C. to C.A.C.

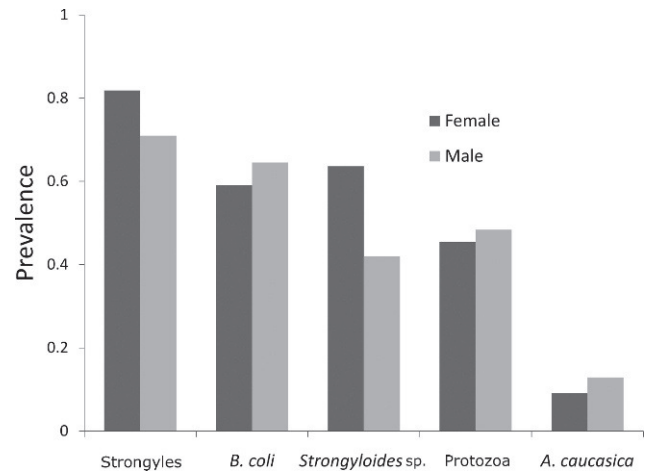


FIGURE 4. Prevalence by baboon gender of strongyles, *Balantidium coli*, *Strongyloides* sp., unidentified protozoans, and *A. caucasica*.

LITERATURE CITED

- ACKERS, J. P., AND D. MIRELMAN. 2006. Progress in research on *Entamoeba histolytica* pathogenesis. *Current Opinions in Microbiology* **9**: 367–373.
- ASH, L. R., AND T. C. ORIHEL. 1997. Atlas of human parasitology, 4th ed. American Society of Clinical Parasitologists, Chicago, Illinois, 410 p.
- BEZJIAN, M., T. R. GILLESPIE, C. A. CHAPMAN, AND E. C. GREINER. 2008. Coprologic evidence of gastrointestinal helminths of forest baboons, *Papio anubis*, in Kibale National Park, Uganda. *Journal of Wildlife Diseases* **44**: 878–887.
- BOWELL, R. J., AND R. K. ANSAH. 1994. Mineral status of soils and forage in the Mole National Park, Ghana and implications for wildlife nutrition. *Environmental and Geochemical Health* **16**: 41–58.
- BRASHARES, J. S. 2003. Behavioral, ecological and life-history correlates of mammal extinctions in West Africa. *Conservation Biology* **7**: 733–743.
- , C. W. EPPS, L. PRUGH, AND C. J. STONER. 2010. Ecological and conservation implications of mesopredator release. In *Trophic cascades*, J. Terborgh, and J. Estes (eds.). Island Press, Washington, D.C., p. 255–274.
- BRONSDON, M. A., M. J. HOMER, J. M. H. MAGERA, C. HARRISON, R. G. ANDREWS, J. T. BIELITZKI, C. L. EMERSON, D. H. PERSING, AND T. R. FRITSCH. 1999. Detection of enzootic babesiosis in baboons (*Papio cynocephalus*) and phylogenetic evidence supporting synonymy of the genera *Entopolypoides* and *Babesia*. *Journal of Clinical Microbiology* **37**: 1548–1553.
- BURTON, C. A., E. B. BUEDI, C. BALANGTAA, D. G. KPILLE, M. K. SAM, AND J. S. BRASHARES. 2010. The decline of lions in Ghana's Mole National Park. *African Journal of Ecology* **49**: 122–126.
- CHAPMAN, C. A., T. R. GILLESPIE, AND T. L. GOLDBERG. 2005. Primates and the ecology of their infectious diseases: How will anthropogenic change affect host-parasite interactions? *Evolutionary Anthropology* **14**: 134–144.
- , M. D. WASSERMAN, T. R. GILLESPIE, M. L. SPEIRS, M. J. LAWES, T. L. SAJ, AND T. E. ZIEGLER. 2006. Do food availability, parasitism, and stress have synergistic effects on red colobus populations living in forest fragments? *American Journal of Physical Anthropology* **131**: 525–534.
- CRAIG, L. E., J. M. KINSELLA, L. J. LODWICK, M. R. CRANFIELD, AND J. D. STRANDBERG. 1998. *Gongylonema macrogubernaculum* in captive African squirrels (*Funisciurus substriatus* and *Xerus erythropus*) and lion-tailed macaques (*Macaca Silenus*). *Journal of Zoology and Wildlife Medicine* **29**: 331–337.
- CROOKS, K. R., AND M. E. SOULE. 1999. Mesopredator release and avifaunal extinctions in a fragmented system. *Nature* **400**: 563–566.
- DASZAK, P., A. A. CUNNINGHAM, AND A. D. HYATT. 2000. Wildlife ecology—Emerging infectious diseases of wildlife—Threats to biodiversity and human health. *Science* **287**: 443–449.

- DE GRUIJTER, J. M., R. B. GASSER, A. M. POLDERMAN, V. ASIGRI, AND L. DIJKSHOORN. 2005. High resolution DNA fingerprinting by AFLP to study the genetic variation among *Oesophagostomum bifurcum* (Nematoda) from human and non-human primates from Ghana. *Parasitology* **130**: 229–237.
- DOBSON, A., AND J. FOFOPOULOS. 2001. Emerging infectious pathogens of wildlife. *Philosophical Transactions of the Royal Society of London Series B—Biological Sciences* **356**: 1001–1012.
- , D. LODGE, J. ALDER, G. S. CUMMING, J. KEYMER, J. MCGLADE, H. MOONEY, J. A. RUSAK, O. SALA, V. WOLTERS, ET AL. 2006. Habitat loss, trophic collapse, and the decline of ecosystem services. *Ecology* **87**: 1915–1924.
- EGGERT, L. S., C. A. RASNER, AND D. S. WOODRUFF. 2002. The evolution and phylogeography of the African elephant inferred from mitochondrial DNA sequence and nuclear microsatellite markers. *Proceedings of the Royal Society of London Series—Biological Sciences* **269**: 1993–2006.
- ESTES, J. A., J. TERBORGH, J. S. BRASHARES, M. E. POWER, J. BERGER, W. J. BOND, S. R. CARPENTER, T. E. ESSINGTON, R. D. HOLT, J. B. C. JACKSON, ET AL. 2011. Trophic downgrading of planet earth. *Science* **333**: 301–306.
- GILLESPIE, T. R., E. V. LONSDORF, E. P. CANFIELD, D. J. MEYER, Y. NADLER, J. RAPHAEL, A. E. PUSEY, J. POND, J. PAULEY, T. MLENGEYA, AND D. A. TRAVIS. 2010. Demographic and ecological effects on patterns of parasitism in eastern chimpanzees (*Pan troglodytes schweinfurthii*) in Gombe National Park, Tanzania. *American Journal of Physical Anthropology* **143**: 534–544.
- GREINER, E. C., AND A. J. MACINTOSH. 2009. Collection methods and diagnostic procedures for primate parasitology. In *Primate parasite ecology: The dynamics and study of host-parasite relationships*, M. A. Huffman and C. A. Chapman (eds.). Cambridge University Press, Cambridge, U.K., p. 3–28.
- HAHN, N. E., D. PROULX, P. M. MURUTHI, S. ALBERTS, AND J. ALTMANN. 2003. Gastrointestinal parasites in free-ranging Kenyan baboons (*Papio cynocephalus* and *P. anubis*). *International Journal of Primatology* **24**: 271–279.
- HIRA, P. R., AND B. G. PATEL. 1980. Human strongyloidiasis due to the primate species *Strongyloides fulleborni*. *Tropical and geographic medicine* **21**: 23–29.
- JACHMANN, H. 2008. Monitoring law-enforcement performance in nine protected areas in Ghana. *Biological Conservation* **141**: 89–99.
- JONES, K. E., N. G. PATEL, M. A. LEVY, A. STOREYGARD, D. BALK, J. L. GITTLEMAN, AND P. DASZAK. 2008. Global trends in emerging infectious diseases. *Nature* **451**: 990–993.
- JOVANI, R., AND J. L. TELLA. 2006. Parasite prevalence and sample size: misconceptions and solutions. *Trends in Parasitology* **22**: 214–218.
- KEESING, F., L. K. BELDEN, P. DASZAK, A. DOBSON, C. D. HARVELL, R. D. HOLT, P. HUDSON, A. JOLLES, K. E. JONES, C. E. MITCHELL, ET AL. 2011. Impacts of biodiversity on the emergence and transmission of infectious diseases. *Nature* **468**: 647–652.
- LAUGHLIN, R. C., AND L. A. TEMESVARI. 2005. Cellular and molecular mechanisms that underlie *Entamoeba histolytica* pathogenesis: Prospects for intervention. *Expert Reviews of Molecular Medicine* **18**: 1–19.
- LAWSON, G. W., J. JENIK, AND K. O. ARMSTRONG-MENSAH. 1968. A study of a vegetation Catena in Guinea savanna at Mole Game Reserve (Ghana). *Journal of Ecology* **56**: 505–522.
- LEGESSE, M., AND B. ERKO. 2004. Zoonotic intestinal parasites in *Papio anubis* (baboon) and *Cercopithecus aethiops* (vervet) from four localities in Ethiopia. *Acta Tropica* **90**: 231–236.
- LUBIMOV, M. P. 1931. *Gongylonema macrogubernaculum* n.sp. (Nematoda) from monkeys. *Parasitology* **23**: 446–448.
- MCGREW, W. C., C. E. G. TUTIN, D. A. COLLINS, AND S. K. FILE. 1989. Intestinal parasites of sympatric *Pan troglodytes* and *Papio* Spp. at two sites: Gombe (Tanzania) and Mt. Assirik (Senegal). *American Journal of Primatology* **17**: 147–155.
- MUNENE, E., M. OTSYULA, D. A. N. MBAABU, W. T. MUTAHI, S. M. K. MURIUKI, AND G. M. MUCHEMI. 1998. Helminth and protozoan gastrointestinal tract parasites in captive and wild-trapped African non-human primates. *Veterinary Parasitology* **78**: 195–201.
- NAUGHTON-TREVES, L., A. TREVES, C. CHAPMAN, AND R. WRANGHAM. 1998. Temporal patterns of crop-raiding by primates: Linking food availability in croplands and adjacent forest. *Journal of Applied Ecology* **35**: 596–606.
- PERMIN, A., L. YELIFARI, P. BLOCH, N. STEENHARD, N. P. HANSEN, AND P. NANSEN. 1999. Parasites in cross-bred pigs in the Upper East Region of Ghana. *Veterinary Parasitology* **87**: 63–71.
- PRUGH, L. R., C. J. STONER, C. W. EPPS, W. T. BEAN, W. J. RIPPLE, A. S. LALIBERTE, AND J. S. BRASHARES. 2009. The rise of the mesopredator. *Bioscience* **59**: 779–791.
- SCHUSTER, F. L., AND L. RAMIREZ-AVILA. 2008. Current world status of *Balantidium coli*. *Clinical Microbiology Reviews* **21**: 626–638.
- SPEARE, R. 1989. Identification of species of *Strongyloides*. In *Strongyloidiasis: A major roundworm infection of man*, D. I. Grove (ed.). Taylor and Francis, London, U.K., p. 11–84.
- STRUM, S. C. 1975. Primate predation: Interim report on the development of a tradition in a troop of Olive baboons. *Science* **187**: 755–757.
- WEBBER, A. D., C. M. HILL, AND V. REYNOLDS. 2007. Assessing the failure of a community-based human-wildlife conflict mitigation project in Budongo Forest Reserve, Uganda. *Oryx* **41**: 177–184.
- WEYHER, A., C. ROSS, AND S. SEMPLE. 2006. Gastrointestinal parasites in crop raiding and wild foraging *Papio anubis* in Nigeria. *International Journal of Primatology* **27**: 1519–1534.
- WOLFE, N. D., P. DASZAK, A. M. KILPATRICK, AND D. S. BURKE. 2005. Bushmeat hunting, deforestation, and prediction of zoonoses emergence. *Emerging Infectious Disease* **11**: 1822–1827.